Chapter 3

Dentinal and pulpal pain

Matti Närhi

Introduction

The dental pulp is exceptionally richly innervated by trigeminal afferent axons (7, 10) that seem to subserve mostly, if not exclusively, nociceptive function (30, 39, 43). Accordingly, they respond to stimuli that induce or threaten to induce injury to the pulp tissue, and their activation may induce defensive, withdrawal-type reflexes in the masticatory muscles (37, 43, 49). The pain responses induced by external stimuli can be extremely intense. The dense innervation of the pulp and dentin gives a morphological basis for the high sensitivity of these tissues. In addition to the afferent sensory nerves, the dental pulp is innervated by autonomic sympathetic efferents that play a role in the regulation of the blood flow in the pulp (47) and, in addition, may have regulatory functions in pulpal inflammation (24, 54). The existence and functional significance of parasympathetic innervation are still controversial (47).

Classification of nerve fibers

Nerves can be divided into different groups according to axon size and structure, which determine the conduction velocities of the individual fibers (22) (Table 3.1). In the nervous system the different-sized fibers are distributed in a functionally meaningful manner, namely thick myelinated fibers in those nerve tracts where fast conduction is demanded and fine-caliber fibers in those tracts where the speed of conduction is not as critical. For example, the efferent Aα-motoneurons, which transmit nerve impulses to the skeletal muscles, have thick myelinated axons and conduction velocities of up to 120 m/s (22). The afferent Aβ-type sensory axons (with conduction velocities of 30–70 m/s) transmit touch and pressure sensations and, usually, their receptors respond to light mechanical forces, i.e. they have low stimulation thresholds (22).

Pain is conducted by two different sets of neurons: thin myelinated Aδ-fibers with conduction velocities of 5–30 m/s and neurons with unmyelinated axons with conduction velocities of 0.5–2.5 m/s. Because of this organization, the sensation perceived in response to noxious stimulation consists of two discrete and different components: first sharp and rather well-localized pain mediated by Aδ-fibers and then delayed, dull pain that is mediated by C-fibers and can radiate to a wide area surrounding the affected tissue (39). The poor localization of the C-fiber pain is due to more extensive convergence of the afferent C-fibers, compared to A-fibers, to the second-order neurons in the brain stem (22). Under experimental conditions, the temporal discrimination and the quality differences of the two pain components can be demonstrated clearly in response to stimulation of extremities (39). The same dichotomy in the quality of pain can be shown when stimulating teeth (30), although temporal discrimination is not as obvious because of the short distance between the brain and the site of stimulation.

Table 3.1 Examples of different nerve fiber types, their functions, diameters and conduction velocities.

Fiber type	Function	Diameter (μm)	Conduction velocity (m/s)
Aα	Motoneurons Muscle afferents	12–20	70–120
Aβ	Mediation of touch and pressure sensations	5–12	30–70
Aδ	Mediation of pain, temperature and touch	2–5	5–30
C	Mostly mediation of pain	0.4–1.2	0.5–2.5

Morphology of intradental sensory innervation

The sensory neurons of the dental pulp have their cell bodies in the trigeminal ganglion (7, 10). The teeth of the upper jaw are innervated by neurons of the maxillary and those of the lower jaw by neurons of the mandibular division of the trigeminal nerve. The pulpal axons are located in the alveolar branches of the nerve and finally

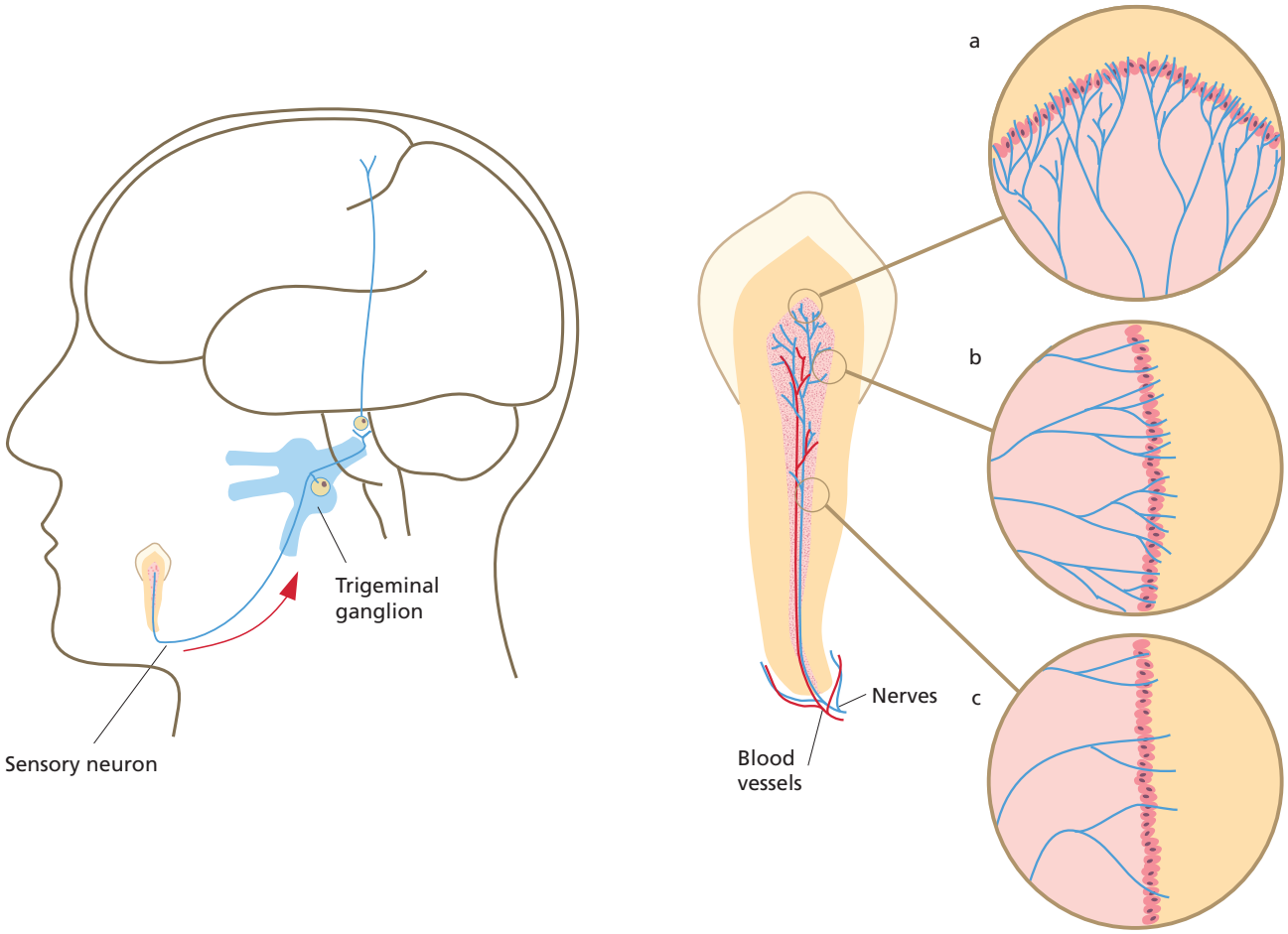

Fig. 3.1 Schematic drawing presenting the innervation of the dental pulp. Several branches from the alveolar nerve enter the apical area of the tooth. Some nerve bundles innervate the periodontal tissues. Multiple bundles enter the pulp in close proximity to the blood vessels through the apical foramen; they branch further on their way to the tooth crown. Most of the intradental axons have their terminals in the pulp/dentin border of the coronal pulp, which is the most densely innervated area in the tissue (a). There are fewer nerve endings in the cervical area (b) and the pulp/dentin border in the root pulp is sparsely innervated (c).

enter the pulp through the apical foramen or multiple foramina of the root apex in close proximity to the intradental blood vessels (Fig. 3.1).

Several hundred axons per tooth enter the pulp at the root apex; for premolars, this number is close to a thousand (7, 26, 29). The nerve fibers enter the tooth pulp in multiple bundles that contain both myelinated and unmyelinated axons (Fig. 3.2) (7, 26, 29). The majority of the axons (70–80%) are unmyelinated (7, 26, 29).

In species as varied as human, cat, dog, monkey and ferret, it appears that there are no gross differences in intradental innervation (7, 10). Rat molars also have similar innervation but in the incisors, which are continuously erupting, the innervation is sparse and of a different structure. For example, these teeth lack dentinal nerve fibers (7, 10).

Only a small proportion of the pulpal afferents terminate in the root. Most of the nerve bundles extend to the coronal pulp, branching on their way (Fig. 3.1). The terminal branch endings are located mostly in the pulp/dentin border area of the coronal pulp (Fig. 3.3). A dense network of fine nerve filaments, known as the nerve plexus of Raschkow, is formed close to the odontoblasts. Several nerve terminals also enter the odontoblast layer and many of them extend into the dentinal tubules (7, 10) (Fig. 3.3). Both morphological and functional studies indicate that the fine nerve filaments in the dentinal tubules are mostly terminals of the myelinated intradental axons (7, 10, 40, 43). Some of the axons also terminate in the deeper parts of the pulp, often in close proximity to the pulpal blood vessels, and they may have a significant role in the mediation of pulpal blood flow responses to external irritation, as well as in pulp tissue inflammation and repair (9, 10, 47, 48; see also Chapter 2).

The terminal branching of the pulpal nerve fibers is extensive (7). Individual myelinated axons may innervate more than 100 dentinal tubules. Accordingly, innervation of the pulp/dentin border is extremely dense. Both myelinated and unmyelinated fibers terminate as free nerve endings. These are the receptors or nociceptors,

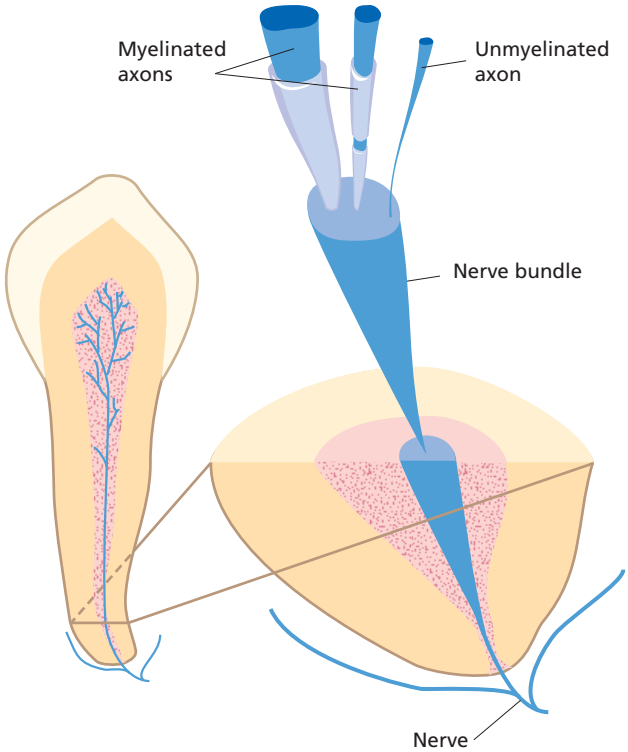

Fig. 3.2 A schematic drawing showing a nerve bundle entering the pulp chamber in the apical area of the tooth. The nerve bundle contains both unmyelinated and myelinated axons of variable sizes.

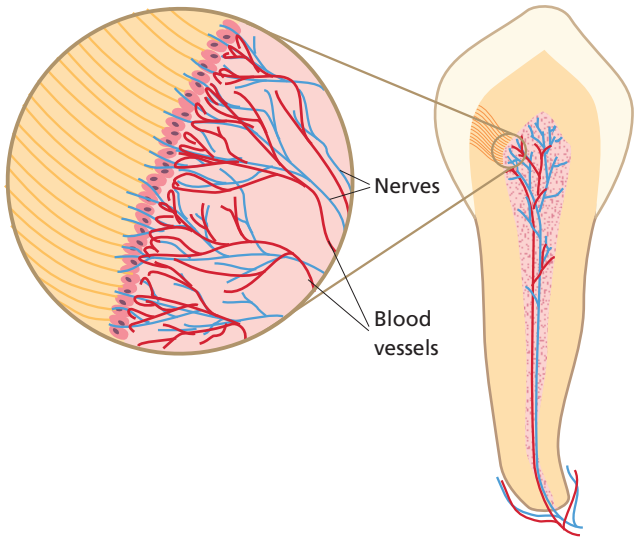

Fig. 3.3 Innervation of the pulp/dentin border in the coronal pulp. The nerve fibers entering the area form a dense network known as the plexus of Raschkow. The fibers form free nerve endings in the peripheral pulp and in the odontoblast layer. Many nerve terminals are also located in the dentinal tubules. Some fibers branch to innervate the adjacent blood vessels (see text for details).

which respond to various external stimuli in normal teeth and to the environmental changes and various inflammatory mediators that occur under pathological conditions.

As in other tissues, the sensory nerves of the dental pulp contain neuropeptides such as substance P and calcitonin gene-related peptide (CGRP) (8–12). Several different neuropeptides have been identified in various parts of the nervous system (18, 34) that act as neuromediators or modulators and have significant regulatory effects on impulse transmission in the central nervous system. Many of them have also been shown to function in peripheral tissues as, for example, mediator substances in the effector organs of the autonomic sympathetic and parasympathetic nerves (34). The sensory neuropeptides in the afferent nerves play an important role in the initial stages of the inflammatory process (neurogenic inflammation) following injury in the peripheral tissues (47, 48) and also seem to regulate the later stages of inflammation and repair (8–12).

The location of the nerve terminals in dentin is limited to the inner 150–200 µm of the tubules (7, 10). The outer layers of dentin are not innervated. It should also be noted that innervation of the dentin is densest in the coronal part, especially in the pulp tips under the cusps, where about 50% of the tubules have been shown to contain nerve fibers (7). Many tubules contain several nerve endings (7, 28). Considering the structural dimensions of dentin it can be estimated that approximately 15 000–20 000 nerve endings/mm^2 exist in the pulp/dentin border area at the pulp tip. Innervation of the pulp/dentin border becomes less dense towards the cervical areas and the number of innervated tubules becomes considerably lower (7, 10). In addition, the distance that the nerve fibers penetrate into the tubules is much shorter than in the coronal areas. In the root, the innervation of the peripheral pulp and dentin is sparse (7). In this respect the structural organization of intradental innervation seems to be poorly correlated to the sensitivity of different dentin areas in the clinical situation, namely, that exposed cervical dentin seems to be especially sensitive. However, this obvious discrepancy can be due to differences in the time the dentin has been exposed and in the responses of the pulp–dentin complex to irritation in the coronal dentin compared with the cervical dentin (see section on dentin hypersensitivity below). The variation in dentinal innervation in different parts of the tooth may explain the different types of pain response induced in the coronal versus the root dentin in human teeth (32).

Some afferent nerve fibers may branch to innervate both the dental pulp and the adjacent tissues or multiple teeth. Such organization may, to some extent, contribute to the poor localization of dental pain and may also allow neurogenic vasodilation and inflammatory reactions to

occur in an area of tissue wider than that affected by the original insult. Correspondingly, within the dental pulp the terminal branching of the nerve fibers may contribute to the spread of the inflammatory reactions (44).

Function of intradental sensory nerves under normal conditions

Knowledge of the function of intradental nerves is mostly based on electrophysiological recordings performed on experimental animals (40, 43, 44, 46). Comparison of the nerve responses to the sensations induced from human teeth with the same stimuli, as well as to the clinical cases of dental pain, has given insight to the contribution of the different intradental nerve fiber groups to different dental pain sensations. The apparently similar structure and function of the innervation in the different species examined (human, monkey, dog, cat and ferret) gives a reasonable basis for such comparisons (Advanced concept 3.1).

As already mentioned, the pulp and dentin are innervated by two different groups of afferents: A- and C-fibers (30, 40, 43). The functional classification is based on the conduction velocities of the axons and corresponds to the morphological findings showing the existence of both myelinated and unmyelinated nerve fibers in the pulp (7, 26,29).

Intradental A- and C-fibers are functionally different (10, 30, 43, 44). The A-fibers respond to various "hydrodynamic" stimuli applied to dentin, such as drilling, probing, air-drying and hypertonic chemical solutions (40, 42, 43). There seems to be a common mechanism of nerve fiber activation in response to the different stimuli. This hydrodynamic mechanism will be described and discussed in detail later in this chapter. The pulpal C-fibers are polymodal, which means that they respond to several different stimuli when they reach the pulp proper (30, 40, 43). The fibers have high thresholds and are activated by intense thermal (heat and cold) and mechanical stimulation (30, 40, 43). They also respond to such inflammatory mediators as bradykinin and histamine (40, 43), which are both formed and/or released in response to tissue injury and associated inflammatory reactions. Thus, the results from the electrophysiological studies indicate that intradental A-fibers are responsible for the sensitivity of dentin and may give the first warning signals whenever dentin is exposed, whereas the C-fibers may be activated mostly under pathological conditions.

Discrete receptive fields of the intradental nerve fibers can be located in either the pulp or dentin (30, 40, 44, 62). The receptive fields of C-fibers are found in the pulp proper and the pulp tissue has to be exposed for their activation. Also, some A-fibers, mostly slowly conducting, have their receptive fields in the pulp and thus cannot be activated by dentinal stimulation (44, 62). On the other hand, the receptive fields of those A-fibers that are activated by hydrodynamic stimulation of dentin can be located by probing the exposed dentin surface (44, 62). In normal teeth the receptive fields are usually small spots a few millimeters in diameter (Fig. 3.4). Some fibers may have two or even three separate receptive fields that can be located at a considerable distance from each other, in the coronal dentin and cervical area in some cases (62). Typically, the receptive fields of individual fibers overlap extensively, meaning that stimulation of a small area in dentin or pulp can activate multiple nerve fibers; this is an important factor, considering the intensity of the pain responses induced by external stimulation. These functional findings are in accordance with the structure of innervation of the pulp/dentin border area, with the extensive and overlapping terminal branching of the individual axons (see above) (Fig. 3.4).

The intradental C-fibers are activated by a direct effect of the applied stimuli on the nerve endings (30, 40, 43). For example, in thermal stimulation the response latencies are rather long and nerve firing does not begin until the temperature within the pulp has changed by several

Advanced concept 3.1 Electrophysiological methods for the recording of pulp nerve activity

Two different methods have been applied in the electrophysiological recordings of pulp nerve function. Recording from dentin is performed by placing the electrodes in dentinal cavities (51). This method allows the discrimination of the action potentials of faster-conducting A-fibers. The activity of the C-fibers cannot be recorded and classification of the individual nerve fibers with respect to their conduction velocities and electrical thresholds is not possible. The recordings were initially performed on cat canine teeth (51). It is important to note that the method has been applied to human teeth as well and those experiments have shown that intradental nerve activity is related to pain sensations perceived by the subjects in response to the external stimuli applied, showing that pulpal nerves are able to conduct nociceptive information (16). In the cat teeth the recordings from dentin have shown that pulpal A-fibers respond to mechanical and osmotic stimulation of dentin (46) and are activated or sensitized by certain inflammatory mediators and heat injury (1, 45, 48). It was also shown that the activity of the intradental A-fibers is greatly affected by changes in the pulpal blood flow.

In single-fiber recordings the individual fibers innervating the examined teeth are dissected from the alveolar nerve and are identified by electrical stimulation of the tooth crown (40). The method has been used in dog, cat and ferret teeth and it allows detailed functional classification of the examined nerve fibers with respect to their electrical thresholds, conduction velocities, receptive fields (the area in the dentin or pulp where an individual fiber can be activated) and sensitivity to a variety of stimuli applied to the dental hard tissues or to the pulp (40, 43).

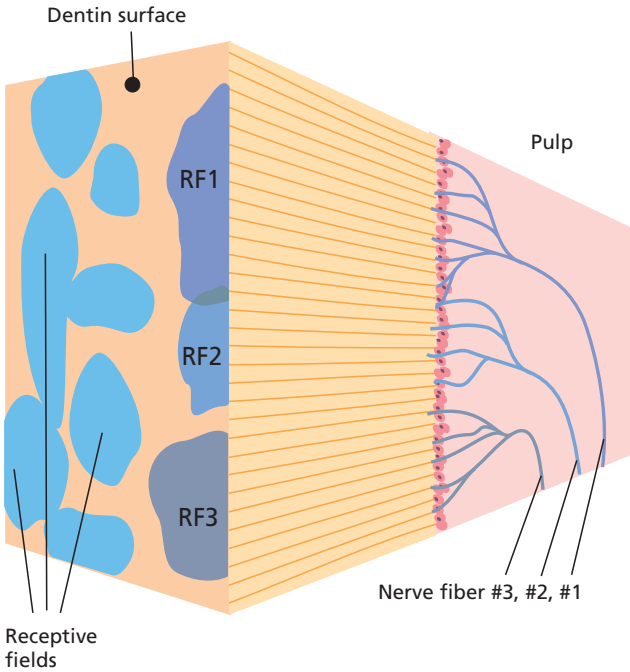

Fig. 3.4 Schematic drawing showing the receptive fields of ten individual pulp nerve fibers on the exposed dentin surface. The receptive fields are of variable shape and overlapping, and in a normal tooth are rather small. The terminal branching of three nerve fibers (fibers 1, 2 and 3) in the pulp/dentin border on the right side of the figure and the corresponding receptive fields (RF1, RF2 and RF3) on the dentin surface are shown as examples. The RF of each individual fiber corresponds to the area in the pulp/dentin border innervated by the particular axon and connected to the receptive field on the dentin surface by the dentinal tubules.

degrees centigrade (30, 40). Similarly, activation of the most slowly conducting Aδ-fibers seems to result from a direct effect of the stimuli on the nerve endings (44, 62). It also seems that the pulpal C-fibers and slowly conducting Aδ-fibers are "silent" in normal healthy teeth and may become active only in cases of pulp injury and inflammation. On the contrary, the A-fibers (mostly faster conducting) responsible for the sensitivity of dentin respond readily whenever dentin is exposed. The nerve activation is immediate or of a very short latency compared with C-fibers, which is in accordance with their activation mechanism (see below).

Comparison of the above-described nerve responses to the pain sensations induced from human teeth under similar stimulation conditions has revealed how different intradental nerve fiber groups may contribute to the different dental pain conditions. For example, "hydrodynamic" stimuli, which activate only pulpal A-fibers, induce sharp pain when applied to dentin in human subjects (42, 43). Intense thermal stimulation of human teeth has been shown to induce an initial sharp pain sensation followed by delayed dull and lingering pain if the stimulation is continued (30). Similar stimulation of the cat canine tooth induces a brief, short latency firing of intradental A-fibers followed by a long latency activation of C-fibers (30, 40, 43). Consequently algogenic (pain-producing) agents, which activate selectively either A- or C-fibers in experimental animals (40, 43), induce sharp or dull and lingering pain in human subjects (2). Altogether, the above results indicate that intradental A-fibers mediate the sharp dental pain sensations and are responsible for dentin sensitivity, whereas C-fibers mediate the dull pulpal pain or toothache connected with pulpitis.

In spite of the type of stimulus applied to a tooth, pain is the only sensation induced in response to activation of the pulpal sensory nerves, according to most studies. The only exception is low-intensity electrical stimulation (39, 43), which can induce so-called prepain sensations that probably result from low-level (liminal) activity in the pulpal nociceptive afferents. Considering any clinical situations when an electric pulp tester is used, it is important to note that the initial sensation at threshold level is usually not painful. When the stimulus intensity is increased, the sensation becomes painful and any other stimulus applied to the tooth induces pain, although its quality may vary in response to different stimuli. The variation is due to differences in the nerve response patterns and the activation of different types of nerve fibers (35).

Sensitivity of dentin: hydrodynamic mechanism in pulpal A-fiber activation

The "hydrodynamic hypothesis" explaining the sensitivity of dentin was first presented by Gysi (23) in 1900. Today it is widely accepted that the sensitivity of dentin is based on hydrodynamic activation of the intradental A-fibers (Fig. 3.5). This concept is supported by a considerable amount of *in vitro* and *in vivo* data from both human and animal experiments (5, 6, 40, 42, 44). It was shown in the early 1960s and in a number of later studies that stimuli inducing pain, when applied to human dentin, are able to induce fluid flow in dentinal tubules *in vitro* (5, 6). The strong capillary forces in the fine tubules cause the hydrodynamic fluid flow. In general, desiccating or evaporative stimuli are the most effective because the capillary force contributes to the outward movements of the tubule contents. It is much more difficult to induce inward fluid flow (6, 50). Moreover, the nerve fibers seem to be more sensitive to outward than inward fluid movements (59). The fluid flow causes mechanical distortion of the tissue in the pulp/dentin border area where most of the nerve endings are located (Figs 3.1 and 3.3–3.5). Accordingly, with all hydrodynamic stimuli the final factor inducing activation of the nerve endings or receptors is a mechanical effect. The results from single pulp nerve recordings showing that

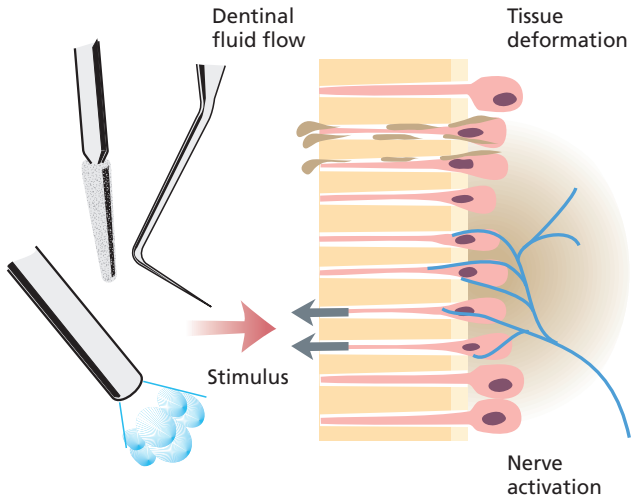

Fig. 3.5 The hydrodynamic mechanism of pulp nerve activation. Any stimulus capable of removing fluid from the outer ends of the dentinal tubules activates hydrodynamic fluid movement. The lost fluid is replaced by an immediate outward flow due to the high capillary forces in the dentinal tubules. The fluid flow causes mechanical distortion of the tissue with the nerve endings in the pulp/dentin border.

individual nerve fibers respond to several different hydrodynamic stimuli are in line with this concept (40, 43, 44).

The fluid flow in the dentinal tubules must be rapid enough to induce sufficient mechanical effect for activation of the nerve endings in the pulp/dentin border. Although there is continuous, slow outward flow in the tubules of exposed dentin due to the high capillary and tissue fluid pressure in the pulp, such a flow is not sufficient to cause nerve activation (50, 58, 59). As already mentioned, stimuli that are able to remove fluid from the tubule apertures, e.g. evaporative or desiccating, are the most effective in activating the pulpal nociceptors because the capillary forces contribute to their effect, resulting in an immediate rapid outward flow (5, 6).

Thermal stimulation is also able to induce hydrodynamic nerve activation because temperature changes cause volume changes in the dentin and tubule contents. However, the temperature change must be rapid enough to cause sufficient fluid flow for nerve activation. In general, cold is more effective than heat because it induces outward fluid movement (6, 59). If intense enough, thermal stimulation (both heat and cold) is able to induce hydrodynamic nerve activation in an intact tooth without any dentin exposure (30). In cases of pulpal inflammation, the intradental nociceptors may become sensitized and activated by a direct effect of heat or cold (43, 44), resulting in a significant increase in the thermal sensitivity of the affected teeth.

Various hypertonic solutions can induce pain when applied to human dentin and activate intradental nerves in experimental animals (3, 5, 43). This action is based on their ability to extract fluid from the dentinal tubules, owing to their high osmotic pressure, resulting in activation of the capillary forces and fluid movement (5, 6). Several studies have shown that the capability of hypertonic solutions to induce pain in human teeth (3, 5, 6) and to activate intradental nerves in experimental animals (43) is related to their osmotic pressure rather than to the chemical composition of the applied solution. Such results give further support to the view that the intradental nerves are activated by the hydrodynamic mechanism.

The experimental induction of pain with hypertonic solutions corresponds to a clinical situation: when a patient complains of dental pain in connection with eating sweets (which form a saturated sucrose solution when mixed with the saliva on the tooth surface), this indicates that dentin with patent tubules is exposed in a tooth or teeth. The exposure can be found on visible occlusal or cervical surfaces but also in the margins of leaky fillings.

A major characteristic of sensitive human dentin is that the dentinal tubules are patent (5, 6, 41, 42). The hydraulic conductance of dentin and the amount and speed of the dentinal fluid flow are, to a great extent, dependent on the dentin having open or blocked tubules (6, 50). In practice, this means that all exposed dentin is not sensitive. For the induction of hydrodynamic fluid flow by capillary forces, removal of fluid from the tubule apertures is essential. Blocking of the tubule openings prevents or reduces the removal of dentinal fluid by the applied hydrodynamic stimuli and thus reduces dentin sensitivity (42).

The effect of the condition of dentin on its sensitivity has been shown in a number of human and animal experiments. For example, after drilling, the dentin surface is covered with a smear layer (drilling debris) and the tubule openings are blocked by the smear plugs. Etching of the exposed surface with acid is able to remove the smear and open the tubules, thus increasing the sensitivity of the dentin to a great extent (5, 6, 40, 42, 43). Blocking of the dentinal tubules, e.g. with oxalates or resins, reduces or abolishes the pulp nerve responses in experimental animals (40, 42, 43) and desensitizes dentin in human subjects (6, 42). It has also been reported that a significant positive correlation exists between the density of the open dentinal tubules and the intensity of the pain responses induced from exposed cervical dentin surfaces (41). In addition to the surface condition, changes occurring deeper in dentin, such as intratubular mineralization and secondary or irritation dentin formation in the pulp, may affect the hydraulic conductance of dentin and thus its sensitivity (6, 50).

The results of the studies listed above give strong but still only indirect evidence supporting the idea that the sensitivity of dentin and intradental A-fiber activation are based on the hydrodynamic mechanism. In fact,

Vongsavan and Matthews (58, 59) have shown a direct relationship between the measured dentinal fluid flow and intradental nerve activity in response to hydrostatic pressure changes in cat teeth.

Other suggested mechanisms of pulp nerve activation include the possibility of direct activation of the nociceptors when dentin is stimulated. However, such a mechanism does not fit with the findings regarding the response properties of intradental nerve fibers and sensory responses in human subjects, showing that algogenic agents are unable to induce nerve activity or pain when applied to peripheral dentin (40, 45). Moreover, as described earlier, neuroanatomical studies have shown that peripheral dentin is not innervated (7). The possible role of the odontoblasts in pain impulse transmission has been discussed and studied but the evidence supporting such a view is vague (see Advanced concept 3.2).

It can be concluded that the sensitivity of dentin is based on hydrodynamic activation of intradental A-fibers and, because patent dentinal tubules are the most important factor for nerve activation, blocking of the tubules would be the method of choice to abolish or prevent dentinal pain symptoms.

Advanced concept 3.2 Odontoblasts as receptor cells?

The possible function of odontoblasts – with their cell processes in the dentinal tubules – as receptor cells has been discussed for a long time (4, 36, 40). It has been suggested that these cells have membrane properties like those of excitable cells and thus would be able to respond to external stimulation by creating a receptor or generator potential (36). This potential would then cause propagation of action potentials, which would be transmitted further in the nerve fibers. However, evidence supporting the idea of receptor cell function of the odontoblasts is controversial. Although the membrane properties with the characteristics of the ion channels and consequent electrical responses of the cells possess some properties similar to neuronal satellite cells (15), their electrophysiological responses do not resemble those of sensory receptors (15, 36). Moreover, morphological studies have been unable to identify any cell contacts between odontoblasts and the adjacent nerve fibers, which would be typical for synaptic connections or electric coupling of the two cells (7, 10, 36). According to morphological studies, the odontoblast process is limited to the inner third or half of the dentinal tubule (7, 28) and thus might not contribute to the sensitivity of peripheral dentin. Also, studies on human teeth and electrophysiological recordings on experimental animals have indicated that dentin can remain sensitive and intradental nerve fibers are activated even when the odontoblast layer has been destroyed (5, 6, 27). In conclusion, on the basis of the currently available evidence, the proposed receptor cell function of odontoblasts seems improbable. However, odontoblasts may have important functions as supporting cells for the fine nerve terminals and in the regulation of environmental conditions, including the composition of dentinal and tissue fluid around nerve endings (10). Such environmental changes may modify the sensitivity of intradental nociceptors.

Responses of intradental nerves to tissue injury and inflammation

In normal intact teeth quite intense external stimuli are needed for the induction of any activity in the pulpal nociceptors. They stay mostly "silent" because their thresholds to various stimuli are high and they are also well protected by the dental hard tissues. As a result, hot or cold foods and drinks do not cause any significant discomfort or pain in a healthy dentition. When dentin is exposed, activation of the hydrodynamic forces can intensify the effects of the external stimuli to a great extent. This allows activation of the intradental A-fibers, mediating sharp dentinal pain. The intensity of the pain is most often still mild or, at greatest, moderate and considerably well localized. Such initial pain responses after dentin exposure can be regarded as a warning signal indicating that dentin is exposed and there are patent dentinal tubules that form a connection between the pulp and the dentin surface. In addition, the protective or withdrawal reflexes induced by the pulpal A-fiber activation in the jaw muscles can modify the masticatory function and contribute to the prevention of excess tooth wear or, in some extreme cases, even cracking of the tooth crown (37, 41, 49).

In inflamed teeth, external stimuli that are not painful in healthy dentition can induce extremely intense pain responses. For example, patients with pulpitis often complain that temperature changes caused by hot or cold foods or drinks induce pain. Also, spontaneous pain without any obvious external irritation may be present. Such symptoms indicate that the pulpal nociceptors have been sensitized, which means that their thresholds to heat, cold and other stimuli are decreased. Also, the silent nociceptors, which do not respond in healthy teeth, may be activated as indicated by the animal experiments (43, 44). The sensitization can be induced by a number of inflammatory mediators that are released and/or formed in the pulp as a result of the insult (40, 43, 44, 46). Owing to the environmental changes and the activation of different mediators, intradental A- and C-fibers may be affected differentially during the progress of the inflammation (40, 43, 44), which may explain the changes in the type of pain symptoms found in clinical cases of pulpitis.

Peripheral neural changes affecting pain responses in inflamed teeth

As in other tissues, injury to the pulp results in an inflammatory reaction, which is an initial promoter of the healing and repair processes. Stimulation of exposed dentin is able to induce injury, which includes dislocation of the odontoblasts into the dentinal tubules as shown in histological studies (5, 6, 27). Also, nerve end-

ings located in the tubules or adjacent to the odontoblasts become damaged (10, 33). Such morphological changes are prominent after dehydrating stimuli and clearly show the efficacy of the hydrodynamic link in the mediation of the stimulation effects from the dentin surface to the pulp. Thus, even a light stimulus such as an air blast can, in fact, be noxious to the pulp owing to the amplifying effect of the capillary and hydrodynamic forces. In spite of the morphological changes with destruction of the odontoblast layer and dentinal nerve endings, the exposed dentin surface remains sensitive in human subjects (5, 6, 33) and intradental nerve fibers in experimental animals maintain their responsiveness to dentinal stimulation (27). Thus, dentin sensitivity is not dependent on the existence of intact odontoblasts or nerve endings in the dentinal tubules.

Neurogenic vasodilation and inflammation

Whenever an insult causes activation of the intradental nociceptors, the initial reaction in the pulp tissue is neurogenic vasodilation mediated by the terminals of the afferent nerve fibers (Fig. 3.6). The propagated action potentials are conducted over the entire cell membrane of the neuron. As a result of ortodromic conduction the impulses reach the trigeminal nuclei and then higher brain centers, including the cortex, to evoke a pain sensation. Antidromic transmission along the collateral terminal branches of the axons results in the release of CGRP and substance P, which induce vasodilation and an increase in the permeability of the blood vessel walls. Because the responses are evoked by the propagated nerve impulses, they are induced immediately by external irritation. Thus, this initial component of the inflammatory reaction is dependent on afferent nerve fibers and is called neurogenic inflammation.

The extensive branching of the pulpal afferents also allows a spread of the neurogenic effects in a wider area of the pulp than was originally stimulated. It is also possible that activation of axons innervating the pulp and the surrounding structures may result in a spread of the neurogenic inflammatory reactions between the adjacent tissues in rather early stages of inflammation (47, 48).

Inflammatory mediators

As outlined in Chapter 2, many different mediators are activated at different stages during the inflammatory reaction and tissue repair, originating from numerous sources, e.g. various tissue components of the pulp, migrating inflammatory cells and the circulating blood. These mediators have important effects in the regulation of the inflammatory reaction and tissue repair. The neurogenic factors interact closely with other mediators (48), e.g. sensory neuropeptides can induce the release of histamine. Autonomic nerves also seem to be involved and it has been suggested that sympathetic nerve endings form contacts with the afferent nociceptive terminals to prevent the release of sensory neuropeptides by a preterminal inhibitory effect (48). The sympathetic nerves may also sprout in carious or inflamed teeth and their other mediator neuropeptide Y (NPY) is also able to prevent CGRP release from the nociceptive sensory nerve endings (17, 20, 54) and, in this way, inhibit the inflammatory reaction.

After heat injury, intradental nerves are sensitized and show ongoing firing and increased responses to thermal stimulation (1). The fact that the induced activation is inhibited by anti-inflammatory drugs indicates that the sensitization is mediated by prostaglandins (1). Serotonin has been shown to sensitize pulpal A-fibers (43, 45). After local application of serotonin into deep dentinal cavities, the responses of A-fibers to hydrodynamic stimulation of dentin are enhanced and they show ongoing activity (43). Bradykinin and histamine activate pulpal C-fibers (40, 43). The differential sensitivity of the intradental

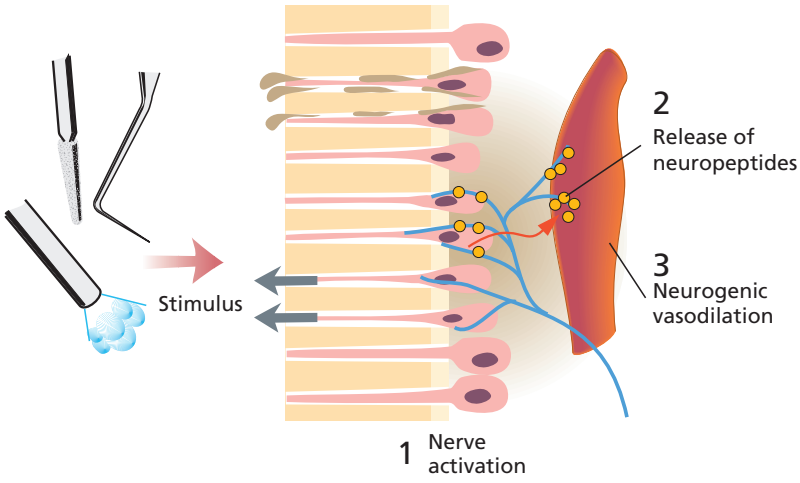

Fig. 3.6 Schematic drawing presenting the induction of neurogenic vasodilation and inflammation in the pulp/dentin border. Activation of the nociceptors by external stimulation results in nerve impulse conduction along all collateral endings of the same axon. Some of the endings are located adjacent to the blood vessels. In response to their activation, the terminals release sensory neuropeptides, which induce vasodilation and increase the permeability of the vessel wall.

A- and C-fibers to various inflammatory mediators may give an explanation of the changes in the type and intensity of the pain symptoms during the progress of pulpal inflammation. The conditions in the pulp tissue, such as alterations in the blood flow and consequently the amount of available oxygen, may also play a role. In general, the unmyelinated C-fibers are more resistant than the myelinated A-fibers to reduced oxygen pressure (18), and single-fiber recordings in cats suggest a similar difference in the intradental nerves (43). Moreover, lowered pH may favor activation of C-fibers via sensitization of TRPV1 receptors (21) and, in fact, recent electrophysiological recordings indicate that C-fibers get more active while the A-fiber activity is reduced in inflamed teeth of experimental animals (38).

Morphological versus functional changes of pulpal nerves in inflammation

In addition to nerve impulse transmission there is another, slower type of signaling between the nerve terminals in the peripheral tissues and the soma of the neuron via axonal transport. This process is bidirectional, including both antero- and retrograde transportation of various cytochemical signaling agents. It allows transmission of information regarding the conditions of the tissues around the nerve endings to the soma of the neuron (10). An injury to the nerve terminals and other tissue components in the pulp results in metabolic activation of the neurons in the trigeminal ganglion. As a result, various signaling molecules, receptors, mediators and modulators are synthesized and transported to the nerve endings in the injured tissue, where they take part in regulation of the inflammatory process and tissue repair (8, 10). Also, profound morphological changes take place in the peripheral nerve terminals (12). These changes are regulated by growth factors and other signaling molecules activated during the process (8, 10). It should also be noted that the action potential firing and the transport of signal molecules into the central nervous system result in discrete cytochemical changes in the second-order neurons of the brain stem (13), which may be related to central sensitization with an increased nociceptive impulse transmission in the trigeminal pain pathways.

The sensory neuropeptides, CGRP and substance P, present in the afferent nerves of normal healthy tissues (8–12) seem to be confined to the fine-caliber pain-mediating afferents (10, 18). It is also indicated that the neuropeptides are predominantly located in the unmyelinated C-fibers and that some small Aδ-fibers are CGRP immunoreactive (31, 35, 48).

Morphological changes shown to take place in response to injury and inflammation in the intradental nerve endings include an increase in their neuropeptide content and sprouting of the nerve terminals (8, 9). As already mentioned, the sensory neuropeptides are able to induce vasodilation and an increase in the permeability of the vessel walls (47, 48). Such vascular reactions are an essential part of the inflammatory reaction and are necessary to satisfy the nutritional needs related to the increased metabolic activity in connection with tissue repair and healing. The above-described structural neural responses are probably important for tissue repair because they allow more effective regulatory function of the nerve terminals in the healing process (11, 12; Key literature 3.1). Also, the time course of the morphological changes in the nerve terminals indicates that they are an essential part of the tissue responses. They are obvious within a couple of days after the insult in the rat molars and they disappear concomitantly with tissue repair and resolution of the insult in reversible cases (8, 9).

The experimental findings regarding the functional correlates of the morphological changes in the pulpal nociceptors described above are limited. Considering the extent of the changes, they may have important effects on the tooth sensitivity. Electrophysiological studies indicate that the receptive fields of single intradental nerve fibers in inflamed dog teeth are wider than in uninflamed controls (44) (Fig. 3.7). Such a change correlates with the morphological findings showing sprouting of the axon terminals (8, 9). Along with the expansion, overlap of the receptive fields of single afferents in dentin is increased, resulting in an increase in the number of fibers activated by stimulation of any particular area in dentin (Fig. 3.7). Accordingly, such changes may contribute to increased dentin sensitivity in inflamed teeth (42, 44).

Electrophysiological experiments have shown that in inflamed teeth the proportion of A-fibers that respond to dentinal stimulation is increased significantly (44), especially in slowly conducting A-δ fibers (44). Many of these fibers are "silent" under normal conditions but seem to become active as a result of the inflammatory reaction (44). The change may be caused by sprouting and consequent formation of new nerve endings and also by sensitization of the original nerve terminals by the

Key literature 3.1

Byers and Taylor (12) (see also: Byers, Suzuki and Maeda; 11) compared the responses after pulp exposure in denervated and normally innervated rat molars and found that the absence of sensory nerves affected the tissue response significantly. Six days after occlusal pulp exposure, the denervated teeth showed more advanced pulp necrosis and less remaining vascular, vital pulp tissue compared with the control teeth with normal sensory innervation. The results indicate that the existence of intact sensory innervation with its responses to tissue injury may be important for regulation of the inflammatory response and consequently for tissue defense and repair reactions in the pulp.

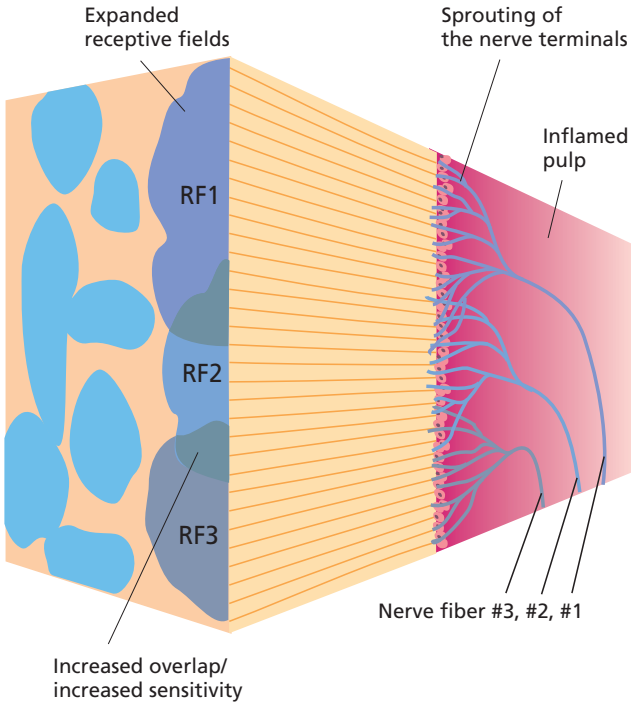

Fig. 3.7 Schematic drawing showing receptive fields of the same intradental nerve fibers as presented in Fig. 3.4. Terminal sprouting of three fibers (fibers 1, 2 and 3) in the pulp/dentin border is shown on the right and consequently the receptive fields (RF1, RF2 and RF3) on the dentin surface have expanded and show increased overlap (cf. Fig. 3.4).

inflammatory mediators. Activation of the "silent" nociceptors may significantly increase the sensitivity of the affected teeth.

Local control of pulpal nociceptor activation

A puzzling clinical finding is that pulpitis may often result in total pulp necrosis without any symptoms. Recent studies have revealed a number of local mediators in the peripheral tissues that regulate the inflammatory process and consequently the sensitivity of the nociceptors (48, 56). In the dental pulp, for example, peripheral endogenous opioids, somatostatin and noradrenaline have been suggested to possess such effects (10, 19, 44, 48). As already mentioned another mediator of the sympathetic fibers seems to inhibit the release of CGRP and, thus, may slow down the inflammatory reaction and nociceptor activation (17, 20, 54). It is indicated that the release of the mediators is closely linked to specific steps in the inflammatory process and is regulated by a negative feedback loop (48). The inhibitory factors may be needed to attenuate the inflammatory reaction and at the same time they inhibit the activation of the pulpal nociceptors. In addition, environmental changes due to alterations in local blood flow are able to modify the responsiveness of the intradental nerves (43, 46).

In addition to the described local factors in the pulp tissue itself, a large number of chemical agents released from carious lesions in decayed teeth and diffusing from the dentin surface through patent tubules may modulate nerve activity (46). Thus, numerous local mechanisms may affect the activation of the intradental nerves and contribute to the wide variability of pulpitis symptoms.

Dentin hypersensitivity

Dentin hypersensitivity is a pain condition that develops following exposure of dentin surfaces. The condition is most often located in the cervical area of the tooth (6, 42, 50) and can be a considerable clinical problem. Typically, patients complain of a sharp or shooting pain that is induced by cold foods or drinks, tooth cleaning or even a light touch of the exposed dentin surface (42, 50, 61). The pain symptoms can be extremely intense, continue for years and thus have great impact on the patient's everyday life. The condition and main features of sensitive dentin, as well as the hydrodynamic nerve activation mechanism as the basis for dentin sensitivity, have been described in detail in an earlier section on dentin sensitivity. The following text will focus on the factors that may prolong the condition, especially the role of inflammatory mechanisms and neural effects.

In favorable cases the repair reactions of the pulp–dentin complex in response to dentin exposure usually lead to a gradual tubule block by intratubular mineralization and/or irritation dentin formation to protect the pulp, leading to natural desensitization of dentin. However, sometimes the dentinal tubules may stay open and the sensitivity of dentin is maintained (6, 42, 50). Such variation in the local responses in dentin is poorly understood. It may be due to a compromised defense capability of the pulp tissue or to intense and continuous external irritation. Possible differences in the repair reactions in the coronal versus cervical pulp–dentin complex may explain why persistent symptoms of dentin hypersensitivity are often found in the cervical and root areas but rarely in the coronal dentin (42, 50). In this respect the structure of the intradental innervation is interesting, showing a dense network of nerve endings in the crown (7); the afferent nerves may play an important role in the repair and defense reactions of the pulp and dentinal mineralization (11, 12, 25). Also, the time course of the dentin exposure may be significant. Gingival recession in the cervical area may cause much faster exposure compared with that caused by attrition on the occlusal or incisal tooth surfaces and thus not allow sufficient time for favorable repair reactions to take place in the pulp. If the dentinal tubules remain open, it may result in an

inflammatory reaction in the pulp (6) and a more or less persistent pain condition.

The method of choice in the treatment of dentinal pain would be blocking of the patent tubules. The action mechanism of a number of products marketed for hypersensitive dentin is based on this principle but in some cases dentin sensitivity may remain even when the tubules have been blocked completely (42). This may be an indication of pulpal inflammation and consequent sensitization of the intradental nociceptors. Thus, the products used in the clinic for the treatment of dentin hypersensitivity may, in some cases, have diagnostic value in the discrimination of inflamed teeth.

Exposed dentin with patent tubules is sensitive if the underlying pulp is vital. The definition "hypersensitive dentin" would implicate that dentin can be more sensitive than normal and it is tempting to state this, considering how extremely intense the dentinal pain responses sometimes can be (42). In fact, the electrophysiological and morphological studies presented above give support to this concept. Namely, local application of serotonin in healthy teeth can increase the sensitivity of intradental A-fibers to dentinal stimulation (42, 43). Moreover, morphological and functional changes showing sprouting of the pulp nerve terminals (8–12), expansion of the receptive fields of pulpal A-fibers (10, 44) and activation of "silent" nociceptors (44) may contribute to an increase in dentin sensitivity in inflamed teeth. Accordingly, in teeth with hypersensitive dentin, pulpal inflammatory reactions may play a significant role in the development and maintenance of the pain symptoms. It should be noted, however, that the above neural changes are reversible. They can be resolved if the pulpal irritation can be abolished and consequently the inflammatory reaction attenuated (8, 9). Thus, effective tubule block may contribute to the reduction of dentin sensitivity both directly, by reducing the hydraulic conductance, and indirectly, by allowing resolution of the pulpal neural changes induced by inflammation.

Central nervous system mechanisms

Both structural and functional changes in the central nervous system take place following peripheral nociceptor activation in response to tissue injury and inflammation. These changes become more prominent in long-lasting pain and may result in persistent alterations in those parts of the pain pathways that participate in the regulation of pain impulse transmission from the periphery to the higher centers of the brain. Results from psychophysiological studies and neurophysiological experiments indicate that central regulation is also important in various dental pain conditions.

The human experiments of Sigurdsson and Maixner (55) showed that radiation of the pain in pulpitis is via secondary hyperalgesia due to central sensitization. By conditioning painful stimulation of the arm, the secondary hyperalgesia could be abolished and the primary source of the pain more accurately localized.

Electrophysiological studies have shown that noxious stimulation of teeth results in discrete cytochemical responses in the second-order neurons of the trigeminal brain stem nuclei mediating orofacial pain (12, 13). These morphological changes are obvious within a few hours after stimulation of the peripheral nociceptors and may represent the first signs of initial sensitization of the central pain pathways. Injuries to the dental nerves caused by tooth extractions and pulpotomies have been shown to induce long-lasting functional changes in the trigeminal brain stem neurons (53). The neurons show increased spontaneous activity and expansion of their peripheral receptive fields, indicating that they have formed connections to peripheral neurons that do not normally activate them.

In summary, it is indicated that inflammation and injury in the peripheral tissues may result in changes in impulse transmission in the central pain pathways. It is not known exactly to what extent the central mechanisms play a role in dental pain conditions but they may be significant, especially in cases of long-lasting pain.

Pain symptoms and pulpal diagnosis

At its worst, pulpitis can cause extremely intense pain. On the other hand, it is a common clinical finding that a large number of teeth develop total pulp necrosis without being painful and with no symptoms (6). As described above, local mechanisms affecting nociceptor activation in the pulp (10, 44, 48) and regulation of the impulse transmission in the central nervous system (55) have significant modulatory effects on the development of pain in pulpitis. The poor correlation between the pain symptoms and the actual condition of the pulp in inflamed teeth has been established in histopathological studies (6, 52). From a diagnostic point of view, the great variation of symptomology in pulpal inflammation is important to note (see Chapters 4 and 14).

The nerve fibers in the pulp may maintain their structural identity even in advanced pulpitis where there is considerable destruction of the other components of the pulp tissue (57). It is not known if the remaining axons are capable of impulse transmission under such conditions but clinical experience shows that pain can be evoked in connection with endodontic treatment of teeth where most of the pulp tissue is necrotic. Comparison of the electrical thresholds of single intradental nerve fibers and those of human teeth also indicates that activation of only a few intradental axons is sufficient to evoke prepain or pain sensations in human teeth (39, 43). With

pulp diagnosis such results are significant because they indicate that a few surviving nerve fibers in a pulp with advanced tissue necrosis may give a positive sensory response to dental stimulation. Thus, evoked sensations in response to electrical stimulation with a pulp tester do not necessarily mean that the pulp is healthy. In fact, dentin can be sensitive in spite of considerable tissue damage in the underlying pulp tissue (6). All these findings indicate that the correlation between the dental sensory responses and the condition of the pulp tissue is poor. Accordingly, it should be noted that pain symptoms are not a reliable basis for pulp diagnostics.

In inflammatory lesions, mediators such as histamine and bradykinin activate C-fibers (40, 43). After reduction of the pulpal blood flow by periapical adrenaline injections they maintain their functional capacity better than A-fibers (35), where the impulse conduction is blocked, probably because of hypoxia in the pulp tissue. This means that during the progress of pulpitis, pulpal C-fibers may maintain their capability for nerve impulse conduction longer than A-fibers. In fact, they can become even more active in the advanced stages of pulpal inflammation owing to their susceptibility to inflammatory mediators and lowered pH (21). The functional properties of the two pulp nerve fiber groups may explain the changes in the quality of pain symptoms during pulpitis: from rather sharp or shooting and quite well localized, to dull and lingering. Thus, the type and duration of symptoms in patients with pulpal inflammation are of diagnostic value and may give some indication of the pulp's condition. However, it must be underlined again that the correlation between the symptoms and histopathological changes in pulpitis is poor and determination of the type and extent of the inflammatory changes on the basis of the symptomology is inaccurate.

References

1. Ahlberg KF. Dose dependent inhibition of sensory nerve activity in the feline dental pulp by antiinflammatory drugs. *Acta Physiol. Scand.* 1978; 102: 434–40.
2. Ahlquist ML, Franzen OG, Edwall LGA, Fors UG, Haegerstam GAT. Quality of pain sensations following local application of algogenic agents on the exposed human tooth pulp: a psychophysiological and electrophysiological study. In: *Advances in Pain Research and Therapy* (Fields HL, ed), vol. 9. New York: Raven Press, 1985; 351–9.
3. Anderson DJ. Chemical and osmotic excitants of pain in human dentine. In: *Sensory Mechanisms in Dentine* (Anderson DJ, ed.). Oxford: Pergamon Press, 1963; 88–93.
4. Avery JK, Rapp R. An investigation of the mechanism of neural impulse transmission in human teeth. *Oral Surg.* 1959; 12: 190–98.
5. Brännström M. A hydrodynamic mechanism in the transmission of pain-producing stimuli through the dentine. In: *Sensory Mechanisms in Dentine* (Anderson DJ, ed.). Oxford: Pergamon Press, 1963; 73–9.
6. Brännström M. *Dentine and Pulp in Restorative Dentistry.* Nacka, Sweden: Dental Therapeutics AB, 1981.

   This book gives an extensive description of different aspects regarding the responses of the pulp–dentin complex to clinical procedures. Dentine sensitivity and dental pain in general are discussed in detail in relation to pulp tissue reactions and pulp diagnosis.
7. Byers MR. Dental sensory receptors. *Int. Rev. Neurobiol.* 1984; 25: 39–94.

   This is a review paper describing the structure of the dental innervation. The morphology of both pulpal and periodontal nerves and receptors is presented and discussed in relation to the functional aspects.
8. Byers MR. Effect of inflammation on dental sensory nerves and vice versa. *Proc. Finn. Dent. Soc.* 1992; 88 (Suppl. 1): 459–506.
9. Byers MR. Neuropeptide immunoreactivity in dental sensory nerves: variation related to primary odontoblast function and survival. In: *Dentine/Pulp Complex* (Shimono M, Maeda T, Suda H, Takahashi K, eds). Tokyo: Quintessence, 1996; 124–9.
10. Byers MR, Närhi M. Dental injury models: experimental tools for understanding neuroinflammatory interactions and polymodal nociceptor function. *Crit. Rev. Oral Biol. Med.* 1999; 10: 4–39.

    This paper presents a comprehensive review on morphological and functional aspects of dental nociceptors. In particular, neural responses to injury and inflammation are covered. The activation mechanisms and afferent functions of the intradental nerves in the mediation of nociceptive information to the brain are presented. The role of the nociceptors in regulation of the inflammatory and repair reactions in the pulp tissue is also described. In addition, the use of intradental nerve stimulation as a pain model and the application of the dental injury models to study the polymodal nociceptor function and neurogenic inflammatory reactions are discussed.
11. Byers MR, Suzuki H, Maeda T. Dental neuroplasticity, neuro-pulpal interactions, and nerve regeneration. *Microsc. Res. Tech.* 2003; 60: 503–15.
12. Byers MR, Taylor PE. Effect of sensory denervation on the response of rat molar pulp to exposure injury. *J. Dent. Res.* 1993; 72: 613–18.
13. Chattipakorn SC, Light AR, Willcockson HH, Närhi M, Maixner W. The effect of fentanyl on *c*-fos expression in the trigeminal brain stem complex produced by pulpal heat stimulation in the ferret. *Pain* 1999; 82: 207–15.
14. Coimbra F, Coimbra A. Dental noxious input reaches the subnucleus caudalis of the trigeminal complex in the rat, as shown by c-fos expression upon thermal or mechanical stimulation. *Neurosci. Lett.* 1994; 173: 201–4.
15. Davidson RM. Neural form of voltage-dependent sodium current in human cultured dental pulp cells. *Arch. Oral Biol.* 1994; 39: 613–20.
16. Edwall L, Olgart L. A new technique for recording of intradental sensory nerve activity in man. *Pain* 1977; 3: 121–6.

    This is the first report on intradental nerve recording in human subjects. The action potentials were recorded from dentin. The nerve responses to dental stimulation were related to pain

responses reported by the subjects. The results show that intradental nerves are able to conduct nociceptive information.

17. El Karim IA, Lamey PJ, Linden GJ, Awawadeh LA, Lundy FT. Caries-induced changes in the expression of pulpal neuropeptide Y. *Eur. J. Oral Sci.* 2006; 114: 133–7.
18. Franco-Cereceda A, Henke H, Lundberg JM, Petermann JB, Hökfelt T, Fischer JA. Calcitonin gene-related peptide (CGRP) in capsaicin-sensitive substance P-immunoreactive sensory neurons in animals and man: distribution and release by capsaicin. *Peptides* 1987; 8: 399–410.
19. Fristad I, Bergreen E, Haug SR. Delta opioid receptors in small and medium-sized trigeminal neurons. *Arch. Oral Biol.* 2006; 51: 273–81.
20. Gibbs JL, Hargreaves KM. Neuropeptide Y Y1 receptor effects on pulpal nociceptors. *J. Dent Res.* 2008; 87: 948–52.
21. Goodis HE, Poon A, Hargreaves KM. Tissue pH and temperature regulate pulpal nociceptors. *J. Dent. Res.* 2006; 85: 1046–9.
22. Guyton AC, Hall JE. *Textbook of Medical Physiology.* Philadelphia, PA: Elsevier–Saunders, 2006.
23. Gysi A. An attempt to explain the sensitiveness of dentine. *Br. J. Dent. Sci.* 1900; 43: 865–8.
24. Haug SR, Heyeraas KJ. Modulation of dental inflammation by the sympathetic nervous system. *J. Dent. Res.* 2006; 85: 488–95.
25. Heyeraas KJ, Haug SR, Bukoski RD, Awumey EM. Identification of Ca^{2+}-sensing receptor in rat trigeminal ganglia, sensory axons and tooth dental pulp. *Calcif. Tisue Int.* 2008; 82: 57–65.
26. Hirvonen TJ. A quantitative electron-microscopic analysis of the axons at the apex of the canine tooth pulp in the dog. *Acta Anat.* 1987; 128: 134–9.
27. Hirvonen T, Närhi M. The effect of dentinal stimulation on pulp nerve function and pulp morphology in the dog. *J. Dent. Res.* 1986; 65: 1290–3.
28. Holland GR. Odontoblasts and nerves; just friends. *Proc. Finn. Dent. Soc.* 1986; 82: 179–89.
29. Holland GR, Robinson PP. The number and size of axons at the apex of the cat's canine tooth. *Anat. Rec.* 1983; 205: 215–22.
30. Jyväsjärvi E, Kniffki K-D. Cold stimulation of teeth: a comparison between the responses of cat intradental A and C fibres and human sensation. *J. Physiol.* 1987; 391: 193–207.
31. Lawson SN. Peptides and cutaneous polymodal nociceptor neurones. *Prog. Brain Res.* 1996; 113: 369–86.
32. Lilja J. Sensory differences between crown and root dentin in human teeth. *Acta Odontol. Scand.* 1980; 38: 285–91.
33. Lilja J, Nordenvall K-J, Brännström M. Dentine sensitivity, odontoblasts and nerves under desiccated or infected experimental cavities. *Swed. Dent. J.* 1982; 6: 93–103.
34. Lundberg JM. Peptidergic control of the autonomic regulation system in the orofacial region. *Proc. Finn. Dent. Soc.* 1989; 85: 239–50.
35. Maggi CA, Meli A. The sensory-efferent function of capsaicin-sensitive sensory neurons. *Gen. Pharmacol.* 1988; 19: 1–43.
36. Magloire H, Vinard H, Joffre A. Electrophysiological properties of human dental pulp cells. *J. Biol. Bucc.* 1979; 7: 251–62.
37. Matthews B, Baxter J, Watts S. Sensory and reflex responses to tooth pulp stimulation in man. *Brain Res.* 1976; 113: 83–94.
38. Modaresi J, Dianat O, Soluti A. Effect of pulpal inflammation on nerve impulse quality with or without anesthesia. *J. Endod.* 2008; 34: 438–41.
39. Mumford JM, Bowsher D. Pain and prothopatic sensibility. A review with particular reference to teeth. *Pain* 1976; 2: 223–43.
40. Närhi MVO. The characteristics of intradental sensory units and their responses to stimulation. *J. Dent. Res.* 1985; 64: 564–71.
41. Närhi M, Kontturi-Närhi V. Sensitivity and surface condition of dentin – a SEM-replica study (abstract). *J. Dent Res.* 1994; 73: 122.
42. Närhi M, Kontturi-Närhi V, Hirvonen T, Ngassapa D. Neurophysiological mechanisms of dentin hypersensitivity. *Proc. Finn. Dent. Soc.* 1992; 88 (Suppl. 1): 15–22.
43. Närhi M, Jyväsjärvi E, Virtanen A, Huopaniemi T, Ngassapa D, Hirvonen T. Role of intradental A- and C-type nerve fibres in dental pain mechanisms. *Proc. Finn. Dent. Soc.* 1992; 88 (Suppl. 1): 507–16.
44. Närhi M, Yamamoto H, Ngassapa D. Function of intradental nociceptors in normal and inflamed teeth. In: *Dentine/Pulp Complex* (Shimono M, Maeda T, Suda H, Takahashi K, eds). Tokyo: Quintessence Publishing, 1996; 136–40.
45. Olgart L. Excitation of intradental sensory units by pharmacological agents. *Acta Physiol. Scand.* 1974; 92: 48–55.
46. Olgart L. The role of local factors in dentin and pulp in intradental pain mechanisms. *J. Dent. Res.* 1985; 64: 572–8.
47. Olgart L. Neural control of pulpal blood flow. *Crit. Rev. Oral Biol. Med.* 1996; 7: 159–71.
48. Olgart L. Neurogenic components of pulp inflammation. In: *Dentine/Pulp Complex* (Shimono M, Maeda T, Suda H, Takahashi K, eds). Tokyo: Quintessence Publishing, 1996; 169–75.

    The afferent nociceptive nerve fibers also have important efferent function in neurogenic regulation of inflammatory and repair reactions in their target tissues. This review paper describes these inflammatory mechanisms, including the mediators involved.
49. Olgart L, Gazelius B, Sundström F. Intradental nerve activity and jaw-opening reflex in response to mechanical deformation of cat teeth. *Acta Physiol. Scand.* 1988; 133: 399–406.
50. Pashley DH. Mechanisms of dentine sensitivity. *Dent. Clin. North Am.* 1990; 34: 449–73.
51. Scott D Jr, Tempel TR. A study in the excitation of dental pulp nerve fibres. In: *Sensory Mechanisms in Dentine* (Anderson DJ, ed.). Oxford: Pergamon Press, 1963; 27–46.
52. Seltzer S, Bender IB, Ziontz M. The dynamics of pulp inflammation: correlations between diagnostic data and actual histopathological findings in the pulp. *Oral Surg. Oral Med. Oral Pathol.* 1963; 16: 969–77.

    In the early 1960s the research group of Dr Seltzer and Dr Bender showed a definite poor correlation between the clinical pain symptoms and the actual histopathological condition of the pulp. The present paper is one of their significant series of studies regarding pulp diagnostics.

53. Sessle BJ. The neurobiology of facial and dental pain: present knowledge, future directions. *J. Dent. Res.* 1987; 66: 962–81.
54. Shimeno Y, Sugawara Y, Iikubo M, Shoji N, Sasano T. Sympathetic nerve fibers sprout into rat odontoblast layer but not into dentinal tubules in response to cavity preparation. *Neurosci. Lett.* 2008; 435: 73–7.
55. Sigurdsson A, Maixner W. Effects of experimental clinical noxious counterirritants on pain perception. *Pain* 1994; 57: 265–75.
56. Stein C. Peripheral mechanisms of opioid analgesia. *Anesth. Analg.* 1993; 76: 182–91.
    It has been thought that opioids, e.g. morphine, have only central effects. This paper presents evidence that they can inhibit nociceptor activation in the peripheral tissues.
57. Torneck CD. Changes in the fine structure of human dental pulp subsequent to caries exposure. *J. Oral Pathol.* 1977; 6: 82–95.
58. Vongsavan N, Matthews B. The relationship between fluid flow in dentine and the discharge of intradental nerves. *Arch. Oral Biol.* 1994; 39: 140S.
59. Vongsavan N, Matthews B. The relationship between the discharge of intradental nerves and the rate of fluid flow through dentine in the cat. *Arch. Oral Biol.* 2007; 52: 640–7.
60. Wells JE, Bingham V, Rowland KC, Hatton J. Expression of Nav1.9 channels in human dental pulp and trigeminal ganglion. *J. Endod.* 2007; 33: 1172–6.
61. West NX. Dentine hypersensitivity. *Monogr. Oral Sci.* 2006; 20: 173–89.
62. Yamamoto H, Narhi M. Function of nerve fibres innervating different parts of dentine. *Arch. Oral Biol.* 1994; 39: 141S.